

Favourable Late Outcome of Percutaneous Coronary Intervention Combined with Aggressive Antiplatelet and Anticoagulant Therapy in Patient with Early Thrombosis in Venous Aortocoronary Bypass Grafts

Marta Kaluzna-Oleksy^{1*}, Bartłomiej Perek², Magdalena Mroz¹, Ewa Straburzynska-Migaj¹ and Stefan Grajek¹

¹Department of Cardiology University of Medical Sciences, Poznan, Poland

²Department of Cardiac and Transplantology Surgery, Chair of Cardio-Thoracic Surgery University of Medical Sciences, Poznan, Poland

*Corresponding author: Marta Kaluzna-Oleksy, Department of Cardiology University of Medical Sciences, Poznan, Poland, Tel: 48 61 8549156; E-mail: marta.kaluzna@wp.pl

Rec date: Apr 15, 2016; Acc date: May 02, 2016; Pub date: May 09, 2016

Copyright: © 2016 Kaluzna-Oleksy M, et al. This is an open-access article distributed under the terms of the Creative Commons Attribution License, which permits unrestricted use, distribution, and reproduction in any medium, provided the original author and source are credited.

Citation: Kaluzna-Oleksy M, Perek B, Mroz M, et al. Favourable Late Outcome of Percutaneous Coronary Intervention Combined with Aggressive Antiplatelet and Anticoagulant Therapy in Patient with Early Thrombosis in Venous Aortocoronary Bypass Grafts. Arch Med. 2016, 8:3

Case Report

A 58-year-old man with hypertension in medical history was admitted to hospital because of myocardial infarction without ST-segment elevation (NSTEMI). Coronary angiography showed critical stenosis in left main-90%, in proximal left anterior descending artery (LAD)-80% and in circumflex artery (LCx)-90% (**Figure 1A**) and borderline stenosis-55% in right coronary artery (RCA). Echocardiography showed impaired global systolic left ventricular (LV) performance with LV ejection fraction-40% and segmental contractility impairment. ECG showed sinus rhythm and global ST-segment depression. The patient underwent emergency Intra Aortic Balloon Pump (IABP)-assisted off-pump CABG (OPCAB). Left Internal Mammary Artery (LIMA) was anastomosed to LAD, and Saphenous Vein Graft (SVG) to the first diagonal branch (DIA-1) and to LCx. No perioperative adverse events were observed (no bleeding, no blood transfusion required). On postoperative day 6 sudden cardiac arrest occurred. After successful resuscitation, coronary angiography was performed. It showed acute thrombus in proximal portions of both venous grafts but not in LIMA (**Figures 1B and 1C**). Percutaneous Coronary Intervention (PCI) with mechanical thrombectomy and Bare Metal Stent (BMS) implantation was performed. Triple Antithrombotic Therapy (TAT) was employed after PCI: clopidogrel and acetylsalicylic acid chronically, and rivaroxaban 15 mg daily for 6 months. Both venous grafts and LIMA were patent without in-stent restenosis in follow-up coronary angiography 22 months after PCI (**Figure 1D**).

Early Saphenous Vein Graft (SVG) failure is a result of thrombosis promoted by perioperative endothelial injury and release of inflammatory cytokines. Moreover, technical surgery-related factors, such as poor distal runoff, graft kinking and small target vessel (leading to discrepancy in diameter between graft and coronary artery) predispose venous grafts to early occlusion. Optimal treatment of early SVG failure is

still disputable and challenging, including type of intracoronary stent (drug eluting or bare metal stent) and medical therapy.

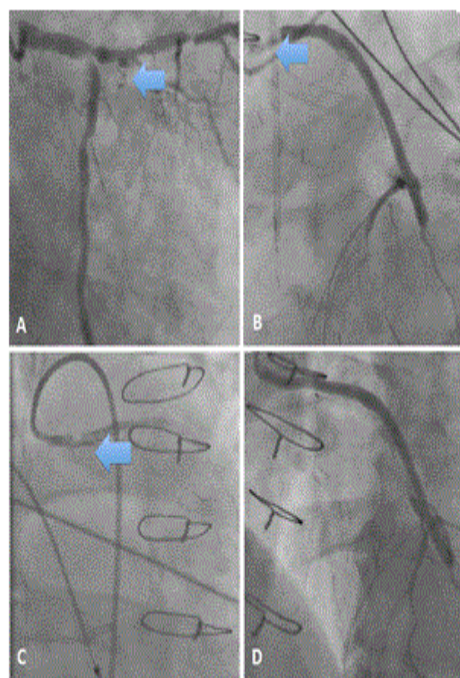


Figure 1: **A)** Critical stenosis in left main, in proximal portion of LAD and LCx. **B)** Acute thrombus in proximal portion of SVG-LCx. **C)** Acute thrombus in proximal portion of SVG-DIA-1. **D)** Patent SVG-LCx (without in-stent restenosis) in follow-up coronary angiography.

The ~15% relative risk reduction of recurrent ischemic events in secondary prevention of acute coronary syndrome by Novel Oral Anticoagulant Therapy (NOA) on top of Dual Antiplatelet Therapy (DPT) was confirmed in two phase III trials APPRAISE-2 and ATLAS-2 and accompanied by reduction

of in-stent thrombosis. Moreover, rivaroxaban 15 mg twice daily for 3 weeks followed by 20 mg once daily provides an effective, safe single-drug treatment of venous thrombosis.

In our case acute thrombosis concerned only venous grafts and led to recurrent acute myocardial infarction with cardiac arrest. Thus, with low bleeding risk (HAS-BLED score=1 points), the patient received DPT and rivaroxaban 15 mg/day. The dose of rivaroxaban was lower because of DPT and lack of recommendation for use of NOA in such situation. It was calculated according to the result of ATLAS ACS-TIMI 46 study. Within 6-months TAT and till 22-months follow-up no bleedings have occurred.

We report this case to point out the problem of SVG disease that results in significant consequences. Optimal use of the most effective antithrombotic agents belongs to important elements of SVG disease preventive strategy, and the dual pathway strategy seems to be the most effective and safe. PCI with BMS deployment supplemented with antiplatelet and anticoagulation therapy may be considered in patients with early venous graft thrombosis. The optimal dosage of NOA is still to be determined.