

Negative Performance of Root Extract of *Onosma dichroanthum* Boiss. on the Burn Wound Healing in an Animal Model

Parastoo Zarghami Moghaddam¹, Mohammad Reza Zolfaghari^{2*}, Ezzat Allah Ghaemi³, Masomeh Mazandarani⁴, Azad Reza Mansourian⁵, Sayeed Ali Taheri⁶

Abstract

Background: *Onosma dichroanthum* Boiss. belongs to the Boraginaceae family which locally known as "Hava Chobeh", and it is considered as one of the most important Mountainous medicinal plants in North of Iran, Its red roots have been used by the rural healers as either singular or combination with other plants as antiseptic and anti-inflammatory to treat the burns and wound healing.

Methods and Findings: In this study, the acetonic extract of plant root was used for the evaluation of its healing efficiency on burn wound model in rat. Burn induced in Wistar rats, and subsequently they were divided into five groups were treated as follow: Group-I ointment containing of extract 2%, Group-II, traditional ointment containing of goat lipid and root extract, Groups-III ointment alone, Group-IV (positive control) the standard drug (silver sulphadiazine) and Group-V (negative control) untreated rats. The assessment the burn area healing was carried out within 14 days. Our results showed that the treated group in I and II, the intensity of wound increased up to the day 8, even the wound diameter much more expanded than negative control group (group V). The best result was demonstrated by Silver sulphadiazine treated group (group IV).

Conclusion: This study shows that *Onosma dichroanthum* Boiss. root did not have any effect on healing of burn wounds in an animal model. Further studies are requiring for assessment of this plant in combination with other plants on burn wound healing.

Keywords: *Onosma dichroanthum* Boiss., root, burn wound , Iran.

- 1 Islamic Azad University of Qom-Branch, Qom, Iran
- 2 Department of Microbiology, Islamic Azad University of Qom- Branch, Qom, Iran
- 3 Department of Microbiology, Infection Disease Research Center, Golestan University of Medical Sciences, Gorgan, Iran
- 4 Department of Botany, Islamic Azad University of Gorgan-Branch, Gorgan, Iran
- 5 Biochemistry and Metabolic Disorder Research Center, Golestan University of Medical Sciences, Gorgan, Iran
- 6 School of Advanced Medical Technologies, Golestan University of Medical Sciences, Gorgan, Iran

*** Corresponding Author:**

Dr. Mohammad Reza Zolfaghari
Postal address: Department of Microbiology,
Islamic Azad University of Qom-Branch, Qom,
Iran

Email: Ali373zolfaghar@yahoo.com

Introduction

Burn is one of the most important factors which alter the total integrity of skin which is the biggest defense barrier of body against external systemic changes, such as oligemic shock, anemia, renal failure, metabolic disturbances and on some condition skin disruption, enhance the death of organism [1]. Thermal injuries are very common and burn cause a huge public health problem [2].

Infection is a serious and significant complication of thermal injury due to presenting a suitable moist and nutrient rich environment for bacterial growth, and it is the cause for about 50-75% of hospital deaths [3, 4].

Studies carried out in Iran indicated that various plants used by rural healer as traditional remedies for treatment of burn and wound. *Onosma dichroanthum* Boiss. is one of the herbs which belongs to Boraginaceae family, locally known as "Hava Chobeh", the extract of red roots of this plant in traditional medicine in combination with goat lipid and other plants such as *Chelidonium majus* and *Hypericum perforatum* are used as burn ointment and antiseptic substance, respectively by the rural healers in Iran.

The roots of Boraginaceae family are very important from medicinal point of view, the roots of some genus of this family is used for the treatment of burn wound and skin diseases, the wound healing characteristic in the plants of this family attrib-

uted to the antibacterial, antiviral, antioxidant and anti-inflammatory activities of secondary metabolites such as phenolic components (flavonoids, phenolic acids), naphthoquinones (alkannin shikonin), rosmarinic acid and caffeic acid [5-7].

Results of Kim et al., (2001), Assimopoulou et al., (2004) and Sekine et al., (1998) showed antioxidant activity of shikonin and alkannin derivatives of roots extract of *Arnebia euchroma* and *Alkanna tinctoria* which are members of same family play an important role in the wound healing. Oxygen free radicals which are produced during injury play an inhibitor role in wound healing and are neutralized by shikonin and alkannin of *Arnebia euchroma* and *Alkanna tinctoria*. [8- 10]

The phytochemical, antioxidant and antibacterial activity of acetonic extract of Hava Chobeh were showed to have antibacterial effect on Gram positive bacteria such as *Staphylococcus aureus* due to their secondary metabolites (phenol, flavonoid and anthocyanin) which are responsible for a wide range of wound infection (unpublished data).

On the bases of above mention studies, we thought that the acetonic extract of Hava Chobeh, play a role in treatment of burn wound, and this present study was designed to evaluate whether this conception is applicable.

Material and methods

Plant material

The roots of *Onosma dichroanthum* Boiss. were collected in KIASAR Mountainous region (1800m) of Mazandaran province in North of Iran during April and May 2010.

This voucher of specimen was identified and has been deposited at the Herbarium of the Ferdowsi University of Khorasan Razavi province.

The roots were washed and dried in a hot air oven at 50°C for 8-10 h. The dried material kept in an air-tight container at 4°C.

Preparation of the extract and ointment

300g of the powder roots of *O. dichroanthum* Boiss. were extracted with acetone (Merck, Germany) by reflux method for 3h [11]. The extract filtered on Whatman No. 1 filter paper, the filtrated solution was subsequently evaporated to dryness in a water bath at 40°C. The yield of dried extract was obtained about 3.4g. Extract was stored at 4 °C and used for preparation of ointment containing of extract.

The combination of Lanoline, Vaseline, liquid Paraffin and Tween 80% were used as base to prepare an ointment extract 2%.

Animals

30 female adult Wistar rats (250-300g) were obtained from the Animal Center of Institute Pasteur of Amol in Iran. Animals were kept single in cages for 2 weeks in standard conditions of temperature (22°C ±2), and a 12h light/dark cycle. During this time standard food and water were provided. The tested rats in this research deprived from the pellet diet 12-15 h prior of the experiment but the animals had access to water.

Burn wound creation

For creation of burn wounds in this experiment, after anaesthetizing rats with intraperitoneal injection of ketamin and xylazine (1.5 mg/kg), the dorsal skin of the Wistar rats were shaved and cleaned with ethanol. Burn wound on dorsal skin of the rat were induced by pressing of a metal rod (2.5 cm diameter) for 10s which were pre-heated in boiling water to about 95°C and produced a second degree burn [12]. Then wound area dressing with sterile gauze. Immediately after burning, rats were resuscitated with an intraperitoneal injection of 1.5 ml sterile saline.

Experimental protocols

After burn wound creation, the animals were divided randomly into five groups containing of 6 rats per group which were treated as following:

Group-I ointment containing of extract 2%, Group-II traditional ointment containing of goat lipid and extract which has been used by rural healer in North provinces of Iran, Groups-III ointment alone, Group-IV (positive control) the standard drug (silver sulphadiazine) and Group-V (negative control) untreated rats. Survey of the burn area healing was observed within 14 days to register wound size, onset of hair growth and the anatomy of subcutaneous lesion at the end of experiment in all groups.

Result

In this study the therapeutic effect was assessed on the reduction of wound diameter area. The findings of wound area measurement demonstrated, that the treated rats with ointment containing *O. dichroanthum* Boiss. extract and traditional ointment in spite of significant increase in the wound region from day 1 up to day 8, in such way, that the wound diameter in day 8 in groups I and II were 36, and 34 mm respectively (**Figure 2**). It should be mentioned that the primary burn diameter in all of the samples was 25mm (**Figure 1A**). In other groups the burn diameter was gradually reduced during 14 days period, and it was shown that from all of these groups, the best result belong to group IV, which silver sulphadiazin

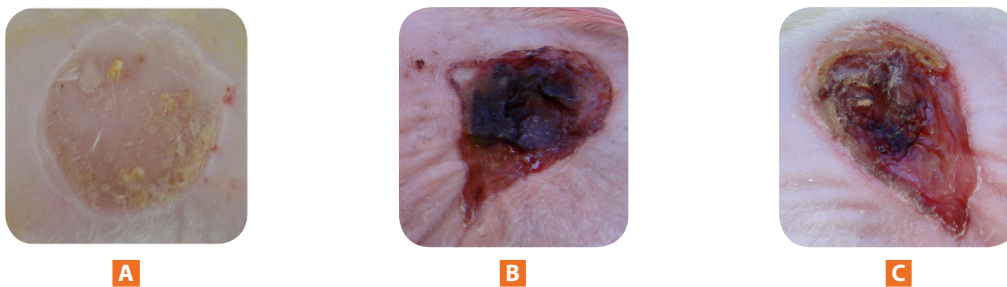


FIGURE 1. Rat dorsal wound area photograph after application of ointment containing of root extract, A: at 0th day , B: at 7th day, C: at 1th day.

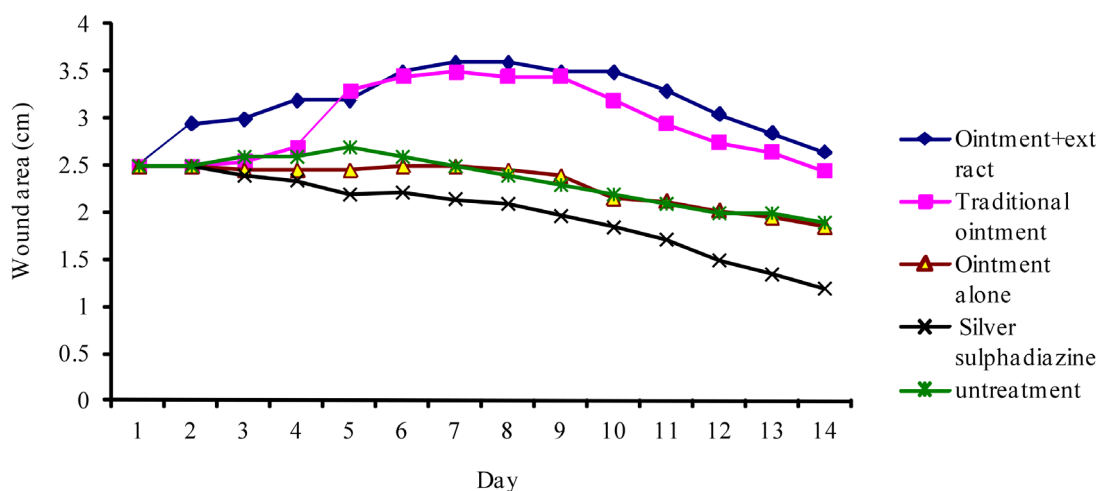


FIGURE 2. Comparison of the wound area at different days.

TABLE 1. The size of wound area in various groups.

Groups		The means of diameter of wound area (mm)				
		2 D	5 D	8 D	12 D	14 D
I	Ointment containing of extract 2%	29±0.37	32±0.74	36±0.52	30±0.13	26±0.16
II	Traditional ointment	25	33±0.23	34±0.18	27±0.39	24±0.39
III	Ointment alone	25	24±0.12	24±0.12	20±0.25	18±0.18
IV	Silversulphadiazine (positive control)	25±0.06	22±0.06	21±0.10	15±0.08	12±0.08
V	untreated rats (negative control)	25±0.06	27±0.12	24±0.08	20±0.12	19±0.12

D: Day.

ointment was applied to the wound (Figure 2, Table1). In group IV two rat were completely recovered, and the remaining in this group, the wound diameter reduced significantly. In group I and II, in study period, there was not any sign of hair growth on the burn region but in group IV the hair growth gradually started from day 11. In groups III the reduction of wound diameter was noticed, and the mean of wound region diameter in day 14 was 18 mm, and the findings in this group indicated similar results with groups V (untreated).

Discussion

Our results indicated that neither the traditional preparation nor the ointment with acetonc extract of *Onosma dichroanthum* Boiss. could have expected on burn wound. So that in the

first days the intensity and diameter of wound increased. This finding is opposite with the general believe in North of Iran's population. We can not find any similar study, which used of the Hava Chobeh extract for the treatment of wounds.

But Ghasemi Pirbalouti et al. (2009) in their results show that, the goat lipid containing of root extract of *Arnebia euchroma* (a member of Boraginaceae family) have significant results in the healing of wound when compared to standard drug (silver sulphadiazine) [13].

Also the results of Akkol et al (2009) indicate that, topical application of hexane and chloroform extracts of *Arnebia densiflora* roots on the incision wound model in mice possess a significant improvement on the burn healing activity when compared to the reference drug Madecassol containing of 1% extract of *Centalla asiatica* [14].

The study of Kumar and Gupta (2009) showed that the treated rats with ointment containing of *Onosma hispidum* (a member of *Onosma* genus belong to Boraginaceae family) and an *Aloe vera* cream (standard), demonstrate both promote wound shrinkage and increase rate of epithelization in lesion area of rats normal and diabetic, when compared with untreated control group [15]. Other studies [16,17] on the members of this family show the remedy effect on wounds. But in study conducted by Nikzad et al [18] the extract of *Arnebia* leaf can not show any suitable effect on healing of burn wounds in rat model, which their finding confirm our results.

The different between our findings and general believe about the efficacy of Hava Chobeh extract may be due to these reasons:

1) The rats in groups I, II partially and in group III shown interest in licking the ointment, and therefore portion of extract on the wound region was not as enough as should be, and this process of licking could not be avoided, by our policy of either by keeping the rat alone or covering the wound region by sterile gauze.

2) The reflex technique was used for preparation of root extract of *O. dichroanthum* Boiss. Therefore the boiling process in this method may possibly denature some of essential constituents of the roots which play an important role in the wound treatment.

3) In traditional medicine, the extract of red roots of this plant in combination with goat lipid and other plants such as *Chelidonium majus* and *Hypericum perforatum* are used as burn ointment and antiseptic substance, Dash and Murthy (2011) offered the use of polyherbal treatment for the healing of wounds which the one of them was *Heliotropium indicum* linn. belong to Boraginaceae family [19], which in our study the singular application of Hava Chobeh as ointment might be the reason for negative performance of this plant in burn wound healing.

Acknowledgements

Authors are thankful to support of the Golestan University of Medical Sciences.

References

1. Chandran PK, Kuttan R (2008) Effect of *Calendula officinalis* flower extract on acute phase proteins, antioxidant defens mechanism and granuloma formation during thermal burns. *J Clin Biochem Nutr* 43: 58-64.
2. Gurunga Sh, Skalko-Basnet N (2009) Wound healing properties of *Carica papaya* latex: In vivo evaluation in mice burn model. *J Ethnopharmacol* 121: 338-341.
3. Shanmuga Priya K, Gnanamani A, Radhakrishnan N, Babu M (2002) Healing potential of *Datura alba* on burn wounds in albino rats. *J Ethnopharmacol* 83: 193-199.
4. Feltsa AG, Giridhara G, Graingerb DW, Slunbt JB (1999) Efficacy of locally delivered polyclonal immunoglobulin against *Pseudomonas aeruginosa* infection in a murine burn wound model. *J Burns* 25: 415-423.
5. Li L, Li MH, Xu L J, Guo N, Wu-Lan TN, Shi RB, Pei-Gen Xiao YP (2010) Distribution of seven polyphenols in several medicinal plants of Boraginaceae in China. *J Med Plants Research* 4(12): 1216-1221.
6. Salman S, Kumbasar S, Ozgen U, Erdogan F, Suleyman H (2009) Contraceptive Effects of *Onosma armeniacum* on Embryo Implantation in Rats. *Cell membranes and free radical* 1:3-1.
7. Petersen M, Simmonds MS (2003) Rosmarinic acid. *J Phytochem* 62(2):121-125.
8. Kim SH, Kang IC, Yoon TJ (2001) Antitumor activities of a newly synthesized shikonin derivative, 2-hyim-DMNQS-33. *Cancer Letter* 172: 171-175.
9. Assimopoulou AN, Boskou D, Papageorgiou VP (2004) Antioxidant activities of alkannin, shikonin and *Alkanna tinctoria* root extracts in oil substrates. *Food Chem* 87: 433-438.
10. Sekine T, Masumizu T, Maitani Y, Nagai T (1998) Evaluation of superoxide anion radical scavenging activity of shikonin by electron spin resonance. *Inter J Pharmaceutics*. 174: 133-139.
11. Cadirci E, Suleyman H, Aksoy H, Halici Z, Ozgen U, Koc A, Ozturk N (2007) Effects on *Onosma armeniacum* root extract on ethanol induced oxidative stress in stomach tissue of rats. *Chemico Biol Interactions* 170: 40-48.
12. Lambrechts S A G, Demidova T N, Aalders M C G, Hasan T, Hamblin M R (2005) Photodynamic therapy for *Staphylococcus aureus* infected burn wounds in mice. *Photochem Photobiol Sci* 4: 503-509.
13. Ghasemi Pirbalouti A, Yousefi M, Nazari H, Karimi I, Koohpayeh A (2009) Evaluation of burn healing properties of *Arnebia euchroma* and *Malva sylvestris*. *Electronic J Bio* 5(3): 62-66.
14. Akkol EK, Kocaa U, Pesin I, Yilmazer D, Tokar G, Yesilada E (2009) Exploring the wound healing activity of *Arnebia densiflora* (Nordm.) Ledeb. by in vivo models. *J. Ethnopharmacol* 124: 137-141.
15. Kumar N and Kumar Gupta A (2009) Wound-Healing Activity of *Onosma hispidum* (Ratanjot) in Normal and Diabetic Rats. *J. Herbs, Spices & Med Plants*, 15: 342-351. J1Wo05

16. Shenoy Ashoka M, Shastry CS, Shetiya P (2011) Evaluation of wound healing activity of *Heliotropium indicum* leaves. *Int. J. Res. Pharmacy* 2(1):279-284.
17. Reddy JS (2002) Wound healing effects of *Heliotropium indicum*, *Plumbago zeylanicum* and *Acalypha indica* in rats. *J. Ethnopharmacol* 79: 249-51.
18. Nikzad H, Atlasi MA, Naseri Esfahani AH, Naderian H, Nikzad M (2010) Effect of *Arnebia* leaf on the healing process of rat's second degree burn. *J. Kashan University of Medical Sciences (Asian J.)* 14(2): 99-106.
19. Dash G K and Murthy PN (2011) The wound healing effects of a new polyherbal formulation. *Scholars Research Library* 3(1): 342-349.

Publish with iMedPub

<http://www.imedpub.com>

- ✓ Archives of Clinical Microbiology (ACMicrob) is a new peer reviewed, international journal with world famous scientist on the editorial board.
- ✓ ACMicrob is an open access journal with rapid publication of articles in all fields and areas of microbiology and infectious diseases.
- ✓ ACMicrob covers all aspects of basic and clinical microbiology relevant to infectious diseases including current research on diagnosis, management, treatment, preventive measures, vaccination, and methodology.
- ✓ Clinical microbiology relevant immunology, pathophysiology, genetics, epidemiological, and genomics studies are also welcome.

Submit your manuscript here:
<http://www.acmicrob.com>