

DOI: 10.21767/2386-5180.100264

# The Radiological Improvement in Brain Atrophy in Syrian Children with Vitamin B<sub>12</sub> Deficiency after Treatment

Alaa Ibrahim\* and Sameer Baklah

Department of Neurology, University Children Hospital in Damascus, UAE

\*Corresponding author: Alaa Ibrahim, Department of Neurology, University Children Hospital in Damascus, UAE, Tel: +971569743016; E-mail: majd.bin.mohammad@live.com

Received Date: November 1, 2018; Accepted Date: November 13, 2018; Published Date: November 15, 2018

Citation: Ibrahim A, Baklah S (2018) The Radiological Improvement in Brain Atrophy in Syrian Children with Vitamin B<sub>12</sub> Deficiency after Treatment. Ann Clin Lab Res Vol.6 No.4:264.

## Abstract

**Background:** The poverty, low social-economic and malnutrition, all of these effects growth and neurological development in Syrian children, especially deficiency of some nutrients from animal source such as Vitamin B<sub>12</sub>. This study aimed to measure the maximal width between Sylvian fissures and measure the maximal width of the extra ventricular subarachnoid space were made in the frontal region in brain by CT or MRI before and after three months of starting treatment with Vitamin B<sub>12</sub> in children (age under 3 year ) have neurological symptoms and brain atrophy before treatment.

**Methods:** Cohort prospective study, children (n=32), between 1-1-2017 and 1-1-2018. This children (age under 3year) were admitted in our hospital and diagnosed with B<sub>12</sub> deficiency, MRI or CT (20 MRI, 12 CT ) imaging before and after three months of starting treatment were performed. The upper limit of normal of Sylvian fissures and maximal width of the extra ventricular sub arachnoid space were made in the frontal region in children has been adopted as reported in neurologic paediatric book.

**Results:** Number of children with mild cerebral atrophy before treatment was 15 (46%) and SD 0.04 and 10 children with moderate cerebral atrophy (31.3%) SD 0.05, the number of children with severe brain atrophies before treatment 7 (21.9%) SD 0.13. The number of children who had normal distance between the sylvius fissures were 31; 96.9% and one child has moderate cerebral atrophy according to Sylvian fissures and no case is left with severe atrophy after treatment.

**Conclusion:** The cerebral atrophy following the Vitamin B<sub>12</sub> deficiency in children because of malnutrition or breast feeding from vegetarian mother reversible completely in early stages.

**Keywords:** Cerebral atrophy; Vitamin B<sub>12</sub> deficiency; Radiological; Syrian children

## Introduction

An adequate Vitamin B<sub>12</sub> status is crucial for the development of central nervous system in children [1], as shown by the clinical picture presented in children with inborn errors of cobalamin metabolism and cobalamin deficiency [2,3]. Although a rapid progress in motor development and improvement in clinical symptoms after cobalamin treatment have been reported [3,4], cobalamin deficiency during infancy, even when optimally treated, may result in permanent developmental disabilities [5].

Vitamin B<sub>12</sub> is rarely shown before the age of four months. The majority of cases were from vegetarians mothers who were dependent on breastfeeding between 6 and 12 months. This deficiency is characterized by central nervous system injury and severe cases of cerebral atrophy [6]. Rapid brain growth during the first two years of age and the process of sheathed axons, which is concentrated during the middle of pregnancy until the second year of life but does not stop and continues until adulthood [7]. Symptoms in older children may pretend eye movement disorders, inflammation of the tongue, pigmentation in the hands in severe cases of vitamin deficiency, epilepsy as a symptom at diagnosis suggests a more severe neurological injury [8].

## Materials and Methods

### Study population and sampling technique

The study period was extended over a period of approximately one year. A prospective descriptive study was conducted on 32 children (16 males and 16 females). Children who visit the Damascus University Paediatric Hospital and diagnosed with Vitamin B<sub>12</sub> deficiency based on the clinical story, the neurological examination, the Vitamin B<sub>12</sub> serum concentration and blood smear. Images were executed with Philips machine 4 mm thickness before and after the treatment, Linear measurements were performed on standardized transverse slices with the use of SIENET Magic View 300-DICOM CD Browser Specified linear measurements on the selected transverse sections were taken, the longest possible distance between Sylvius fissures was measured before treatment and then the radiographic image was

returned three months after the starting of the B<sub>12</sub> (1000 mcg) injection there by daily for two weeks and then a weekly for two months and then one injection monthly for two years. Children were classified by degrees of cerebral atrophy into three groups based on the normal maximum distance between Sylvian fissures in children (0-0.760 cm). Groups were classified as follows: severe cerebral atrophy ( $\geq 1.1$  cm) moderate cerebral atrophy (0.910-1.1 cm) and mild cerebral atrophy (>0.760 and <0.910) cm.

The children were again classified according to degrees of cerebral atrophy after treatment and comparison of results. For the measurements of the maximal width of the extra ventricular sub arachnoid space were made in the frontal region Groups were classified as follows. Upper limit of normal spaces is 0.580 cm, mild atrophy (>0.580 cm <0.90 cm) moderate atrophy (0.90 cm-1.10 cm) severe atrophy  $\geq 1.1$  cm). The upper limit of normal of Sylvian fissures and maximal width of the extra ventricular sub arachnoid space were made in the frontal region in children has been adopted as reported in Fenichel's clinical pediatric neurology book [9].

### Ethical acceptance

Written informed consent was obtained from the mothers before enrolment. For parents of children who are unable to read and write, the research objective is explained to them and their oral consent is taken in the presence of a member of their family. All were assured that all data collected would be confidential and available for the researcher only. It was explained to the participants that they had the right to withdraw from the research any tests were free and the participants did not pay for it.

### Inclusion and exclusion criteria

Children with Vitamin B<sub>12</sub> deficiency due to mal absorption, metabolic disease or surgical intervention in abdomen are excluded in our study. The cases included children who had vitamin deficiency due to breastfeeding of vegetarians and malnutrition.

### Data analysis

Data from all the children studied were collected and analysed using the statistical analysis program SPSS v25, using the normality test, descriptive, chi square tests. By comparing the statistical values with the p value of 0.05/0.05, the difference between the values is statistically significant if the probability value is  $p < 0.05$

## Results

### Sylvian fissures

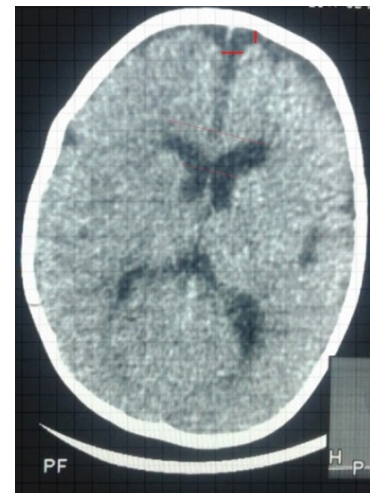**Before treatment:** Number of children with mild cerebral atrophy before treatment was 15 (46%) and SD 0.04 and 10 children with moderate cerebral atrophy (31.3%) SD 0.05, the

number of children with severe brain atrophies before treatment 7 (21.9%) SD 0.13.

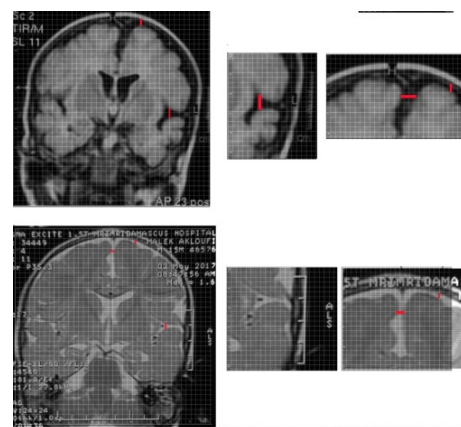
**After treatment:** The number of children who had normal distance between the sylvius fissures were 31 (96.9%) and one child has moderate cerebral atrophy according to Sylvian fissures and no case is left with severe atrophy after treatment (**Figures 1-5**).

### Maximal width of the extra ventricular sub arachnoid space

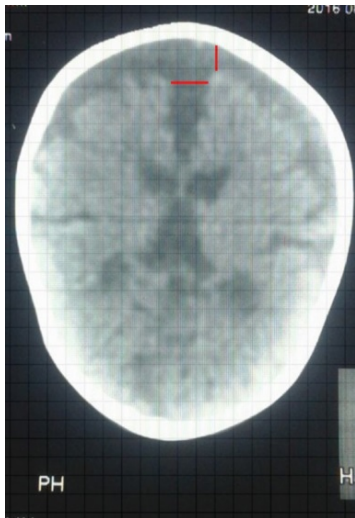
**Pre-treatment:** 22 children with mild cerebral atrophy 68.7%. With median 0.77 cm and SD 0.08 cm and 5 children with moderate cerebral atrophy with median 0.98 cm and SD 0.07 cm and 5 children with severe cerebral atrophy (15.6%) with median 1.28 cm and SD 0.11 cm.



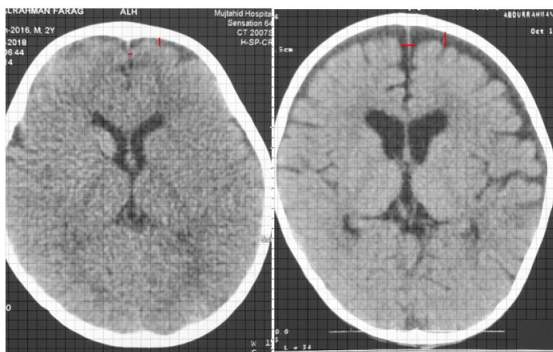
**Figure 1** Showing the change in the Brain atrophy after B<sub>12</sub> treatment to patient 1.



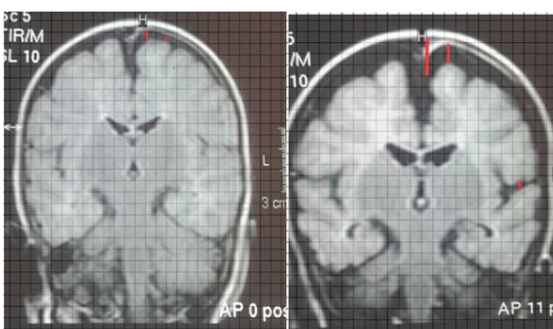
**Figure 2** Showing the change in the Brain atrophy after B<sub>12</sub> treatment to patient 1 in detail.



**Figure 3** Figures showing the change in the Brain atrophy after B<sub>12</sub> treatment to patient 2.



**Figure 4** Figures showing the change in the Brain atrophy after B<sub>12</sub> treatment to patient 3.



**Figure 5** Figures showing the change in the Brain atrophy after B<sub>12</sub> treatment to patient 4.

atrophy with (18.8%) (Median=0.74, SD 0.10) One child still has severe cerebral atrophy.

**Table 1** Degree of cerebral atrophy before treatment (width between Sylvian fissures).

| Degree of cerebral atrophy | Before treatment |            |      |
|----------------------------|------------------|------------|------|
|                            | Number           | Proportion | SD   |
| Mild                       | 15               | 46.8%      | 0.04 |
| Moderate                   | 10               | 31.3%      | 0.05 |
| Severe                     | 7                | 21.9%      | 0.13 |

**Table 2** Degree of cerebral atrophy before and after treatment (width of sylvius fissures).

| Degree of cerebral atrophy (according to Sylvian fissures only) | Before treatment |            | After treatment |            |
|-----------------------------------------------------------------|------------------|------------|-----------------|------------|
|                                                                 | Number           | Proportion | Number          | Proportion |
| Normal width of Sylvian fissures                                | --               | --         | 31              | 96.9%      |
| Mild                                                            | 15               | 46.8%      | --              | --         |
| Moderate                                                        | 10               | 31.3%      | 1               | 3.1%       |
| Severe                                                          | 7                | 21.9%      | --              | 0%         |

**Table 3** The change in the values of the distance between the sylvius and the subarachnoid distance before and after treatment.

| Variables                                                   | Median | SD   | Min  | Max  |
|-------------------------------------------------------------|--------|------|------|------|
| Distances between Sylvius fissures before treatment (in cm) | 0.98   | 0.22 | 0.77 | 1.62 |
| Distances between sylvius fissures after treatment (in cm)  | 0.33   | 0.28 | 0.0  | 0.93 |

**The result of comparing the distance between the sylvius fissures before and after treatment is significant**

There are significant differences in the value of the distance between pre and post treatment. And this result according to the probability value (p-value=0.001) which is smaller than the moral level (0.05).

**The results of comparing subarachnoid distance before and after treatment are significant**

There are statistically significant differences in the value of the pre-treatment distance and the magnitude of the probability value (p-value=0.001). In this study, we found that

**After treatment:** 25 children with normal limit width (78.1%) (Median=0.28, SD 0.12) 6 children have mild cerebral

some images improvement in Sylvian fissures before subarachnoid spaces.

**Table 4** Several statistical criteria for subarachnoid distance before treatment.

| Variables              | Median | SD   | Min  | Max  |
|------------------------|--------|------|------|------|
| Sylvian fissures       | 0.87   | 0.22 | 0.33 | 1.42 |
| Subarachnoid distances | 0.39   | 0.23 | 0    | 0.92 |

**Table 5** Several statistical criteria for subarachnoid distance after treatment.

| Variables | Before treatment |            |        |      |
|-----------|------------------|------------|--------|------|
|           | Number           | Proportion | Median | SD   |
| Mild      | 22               | 68.7 %     | 0.77   | 0.08 |
| Moderate  | 5                | 15.6%      | 0.98   | 0.07 |
| Severe    | 5                | 15.6%      | 1.28   | 0.11 |

**Table 6** Showing degree of cerebral atrophy according to subarachnoid distances.

| Degree of cerebral atrophy according to subarachnoid distances. | After treatment |            |        |      |
|-----------------------------------------------------------------|-----------------|------------|--------|------|
|                                                                 | number          | proportion | median | SD   |
| Normal width                                                    | 25              | 78.1%      | 0.28   | 0.12 |
| Mild                                                            | 6               | 18.8%      | 0.74   | 0.10 |
| Moderate                                                        | 1               | 3.1%       | 0.92   | --   |
| Severe                                                          | 0               | 0%         | --     | --   |

**Table 7** Table shows several statistical criteria for Vitamin B<sub>12</sub>.

| Variables                        | Before treatment | After treatment | p-value |
|----------------------------------|------------------|-----------------|---------|
| Median Width of sylvian fissures | 0.98             | 0.33            | 0.0     |
| Median Subarachnoid width        | 0.87             | 0.39            | 0.0     |

**Table 8** Table shows several statistical criteria (Max, Min, SD and Median) for vitamin B<sub>12</sub>.

| Concentration of Vitamin B <sub>12</sub> in serum (ng/ml) | Median | SD  | Min | Max |
|-----------------------------------------------------------|--------|-----|-----|-----|
|                                                           | 249    | 104 | 44  | 400 |

### Compared with vitamin B<sub>12</sub> levels before treatment

There were no significant differences between the degrees of atrophy and the vitamin concentration of the value of

probability (p-value =0.717), which is greater than the level of p-value (0.05) (Tables 1-9).

**Table 9** Table shows several statistical criteria (Proportion and number) for Vitamin B<sub>12</sub>.

| Variables  | Number | Proportion |
|------------|--------|------------|
| Normal     | 22     | 68.7%      |
| Deficiency | 10     | 31.3%      |
| Total      | 32     | 100%       |

## Discussion

In this study ~96.8 of all cases response to treatment with Vitamin B<sub>12</sub> completely. Vitamin B<sub>12</sub> is a vitamin which is important for the development of the nervous system in children. However, the mechanism it plays in development of the nervous system is still not fully understood [10,11]. This vitamin plays a role as a cofactor in the re-methylation of homocysteine and methyl malonyl CoA degradation. Vitamin B<sub>12</sub> deficiency is thought to cause accumulation of guanidoacetate, leading to neurotoxicity. These may lead to demyelination, axonal degeneration, and neuronal death [12,13] Even though clinical signs of Vitamin B<sub>12</sub> deficiency have been described half a century ago [14], studies on radiological findings are limited [11 and 15-17] Determined common radiological findings in the studies which are mostly case reports has been cerebral atrophy. Taskesen et al., in their recently published study, determined abnormal MRI in 10 (67%) of 15 infants with Vitamin B<sub>12</sub> deficiency, and the most often determined findings were thinning of the corpus callosum and brain atrophy [15-17]. Lövlblad et al. [11] found MRI of the brain revealed severe brain atrophy with signs of retarded myelination, the frontal and temporal lobes being most severely affected in their case report in this study, we found that some images improvement in Sylvian fissures before subarachnoid spaces. There are several possible explanations for the discrepancy. First, cortical thickness in Sylvian fissures measurements may be more sensitive for treatment in than subarachnoid spaces, we need more study to know the most region in brain sensitive to treatment with Vitamin B<sub>12</sub> and the first region effects in deficiency, temporal or frontal region. Lam et al. [18] found small pons, partial vermian dysgenesis, and abnormal signal in both basal ganglia with MRI in one patient. Vitamin B<sub>12</sub> required for the development of the central nervous system in children. Brain MRI thinning of the corpus callosum and brain atrophy should alert the radiologist for Vitamin B<sub>12</sub> deficiency in children. After treatment, radiological response was usually positive in 96.8% in our study. As neuroimaging indicator to follow-up the response numerically for the therapy and diagnosis for the cases with Vitamin B<sub>12</sub> deficiency. The clinical picture is the most important factor for the diagnosis of Vitamin B<sub>12</sub> deficiency because there is no diagnostic laboratory test, in our study 68.7% of the patients have normal B<sub>12</sub> concentration and the diagnosed done by the clinical picture and neurological examination, blood smear and radiological study.

When there is a discrepancy between laboratory results, serum Vitamin B<sub>12</sub> and strong clinical suspicion, treatment should not be delayed to avoid non-reversible neurodegenerative changes [19].

## Conclusion

Cobalamin is important for the rapid development of nervous system [20]. Long-term effects of a temporary moderate deficiency are unknown, but cobalamin deficiency should be considered in young, mainly breastfed infants with feeding difficulties, subtle neurologic symptoms, and delayed motor development.

## Acknowledgments

We thank all mothers and infants for their participation in the study.

## Conflict of Interest

The authors declare no conflict of interests.

## References

1. Stiles J, Jernigan TL (2010) The basics of brain development. *Neuropsychol Rev* 20(4): 327-348.
2. Rosenblatt DS, Whitehead VM (1999) Cobalamin and folate deficiency: acquired and hereditary disorders in children. *Semin Hematol* 36(1): 19-34.
3. Zengin E, Sarper N, Caki Kilic S (2009) Clinical manifestations of infants with nutritional vitamin B deficiency due to maternal dietary deficiency. *Acta Paediatr* 98(1): 98-102.
4. McPhee AJ, Davidson GP, Leahy M, Beare T (1988) Vitamin B<sub>12</sub> deficiency in a breast fed infant. *Arch Dis Child* 63 (8): 921-923.
5. Graham SM, Arvela OM, Wise GA (1992) Long-term neurologic consequences of nutritional vitamin B<sub>12</sub> deficiency in infants. *J Pediatr* 121(5): 710-714.
6. Black MM (2008) Effects of vitamin B<sub>12</sub> and folate deficiency on brain development in children. *Food Nutr Bull* 29(2): 126-131.
7. Georgieff MK (2007) Nutrition and the developing brain: nutrient priorities and measurement. *Am J Clin Nutr* 85(2): 614-620.
8. Smith J, Coman D (2014) Vitamin B<sub>12</sub> Deficiency: an Update for the General Paediatrician. *Pediatr Therapeut* 4(188): 2161-0665
9. J. Eric Piña-Garza, MD (1993) Fenichel's clinical pediatric neurology book, Disorders of Cranial Volume and Shape pp: 350.
10. Black MM (2008) Effects of vitamin B<sub>12</sub> and folate deficiency on brain development in children. *Food Nutr Bull* 29(Suppl 2): 126-131.
11. Lövblad K, Ramelli G, Remonda L, Nirkko AC, Ozdoba C, et al. (1997) Retardation of myelination due to dietary vitamin B<sub>12</sub> deficiency: cranial MRI findings. *Pediatr Radiol* 27(2): 155-158.
12. Emadfa I, Singer I (2009) Vitamin B<sub>12</sub> and homocysteine status among vegetarians: A global perspective. *Am J Clin Nutr* 89(5): 1693-1698.
13. Graham SM, Arvela OM, Wise GA (1992) Long-term neurological consequences of nutritional VB<sub>12</sub> deficiency in infants. *J Pediatr* 121(5): 710-714.
14. Honzik T, Adamovicova M, Smolka V, Magner M, Hrubá E, et al. (2010) Clinical presentation and metabolic consequences in 40 breastfed infants with nutritional vitamin B<sub>12</sub> deficiency-what have we learned?. *Eur J Paediatr Neurol* 14(6): 488-495.
15. Taşkesen M, Yaramış A, Piriñcioglu AG, Ekici F (2011) Cranial magnetic resonance imaging findings of nutritional B<sub>12</sub> deficiency in 15 hypotonic infants. *Eur J Paediatr Neurol* 16(3): 266-270.
16. Von Schenck U, Gotze CB, Koletzko B (1997) Persistence of neurological damage induced by dietary vitamin B<sub>12</sub> deficiency in infancy. *Arch Dis Child* 77(2): 137-139.
17. Horstmann M, Neumaier-Probst E, Lukacs Z, Steinfeld R, Ullrich K, et al. (2003) Infantile cobalamin deficiency with cerebral lactate accumulation and sustained choline depletion. *Neuropediatrics* 34(5): 261-264.
18. Lam WW, Wang ZJ, Zhao H, Berry GT, Kaplan P, et al. (1998) 1H MR spectroscopy of the basal ganglia in childhood: A semiquantitative analysis. *Neuroradiology* 40(5): 315-323
19. Devalia V, Hamilton MS, Molloy AM (2014) Guidelines for the diagnosis and treatment of cobalamin and folate disorders. *Br J Haematol* 166(4): 496-513.
20. Rosenblatt DS, Cooper BA (1990) Inherited disorders of vitamin B<sub>12</sub> utilization. *Bioessays* 12(7): 331-334.